

ined tissue samples that were not required for the diagnostic studies to determine the extractable levels of validated tissue profibrotic markers<sup>3</sup> and compared the levels in the two groups. Fragments from five normal lungs were also included in the study as a control. The 20 patients in the treated group and the untreated group had a mean forced vital capacity that was 70% of the predicted volume and a mean diffusing capacity for carbon monoxide that was 55% of the predicted volume. (The clinical and demographic characteristics of the patients are provided in the Supplementary Appendix, available with the full text of this letter at NEJM.org.)

Among the patients who received EGCG, tissue levels of extractable type I collagen, which was probably either poorly cross-linked or new collagen, were near the normal reference levels and were significantly lower than the levels in the untreated patients ( $P=0.001$ ) (Fig. 1A and 1B). Likewise, in the treated patients, tissue levels of snail family transcriptional repressor 1 (SNAIL1) and phosphorylated SMAD3 were also significantly lower than those in the control cohort. There was no evidence of a between-group difference in levels of total SMAD3 or alpha smooth-muscle actin ( $\alpha$ -SMA) among the various groups. The empirical correlation between the degree of reduction in collagen I protein and phosphorylated SMAD3 levels was positive, which was consistent with collagen expression driven by TGF $\beta$ 1 signaling (Fig. 1C). We observed no evidence of correlation with collagen messenger RNAs (see the Supplementary Appendix), which suggests that the inhibition of LOXL2 collagen cross-linking may substantially contribute to reduced accumulation of collagen I.

Serum biomarkers indicative of progression of idiopathic pulmonary fibrosis (IPF) do not decrease in response to drugs that have been approved for use in such patients by the Food and Drug Administration.<sup>4,5</sup> Surprisingly, during 14 days of EGCG treatment, we found decreased

amounts of two fibroblast-derived serum biomarkers, cartilage oligomeric matrix protein and periostin, which have been associated with IPF activity and prognosis,<sup>5</sup> a finding that is consistent with an antifibrotic effect (Fig. 1D and 1E). Our data suggest that in patients with interstitial lung disease, EGCG treatment was associated with a reduction in fibrogenesis and thus may provide equipoise for the performance of a long-term, randomized clinical trial of EGCG involving patients with this condition.

Harold A. Chapman, M.D.

Ying Wei, M.D.

University of California, San Francisco  
San Francisco, CA  
hal.chapman@ucsf.edu

and Others

Drs. Chapman and Wei contributed equally to this letter.

A complete list of authors is available with the full text of this letter at NEJM.org.

Supported by a grant (to Dr. Chapman) from the Three Lakes Foundation and grants (R01 HL142265, to Dr. Chapman; R21 AG052744, to Dr. Le Saux; and K23 HL138190, to Dr. Oldham) from the National Institutes of Health. Authors who were employees of Pliant Therapeutics performed assays using their Nanostring equipment at no cost to the study.

Disclosure forms provided by the authors are available with the full text of this letter at NEJM.org.

1. Akhurst RJ, Hata A. Targeting the TGF $\beta$  signalling pathway in disease. *Nat Rev Drug Discov* 2012;11:790-811.
2. Lacouture ME, Morris JC, Lawrence DP, et al. Cutaneous keratoacanthomas/squamous cell carcinomas associated with neutralization of transforming growth factor  $\beta$  by the monoclonal antibody fresolimumab (GC1008). *Cancer Immunol Immunother* 2015;64:437-46.
3. Wei Y, Kim TJ, Peng DH, et al. Fibroblast-specific inhibition of TGF- $\beta$ 1 signaling attenuates lung and tumor fibrosis. *J Clin Invest* 2017;127:3675-88.
4. Maher TM, Stowasser S, Nishioka Y, et al. Biomarkers of extracellular matrix turnover in patients with idiopathic pulmonary fibrosis given nintedanib (INMARK study): a randomised, placebo-controlled study. *Lancet Respir Med* 2019;7:771-9.
5. Neighbors M, Cabanski CR, Ramalingam TR, et al. Prognostic and predictive biomarkers for patients with idiopathic pulmonary fibrosis treated with pirfenidone: post-hoc assessment of the CAPACITY and ASCEND trials. *Lancet Respir Med* 2018;6: 615-26.

DOI: 10.1056/NEJMc1915189

## A Locally Transmitted Case of SARS-CoV-2 Infection in Taiwan

**TO THE EDITOR:** Since December 2019, an outbreak of infection with the novel coronavirus (SARS-CoV-2) has developed in Wuhan, China,

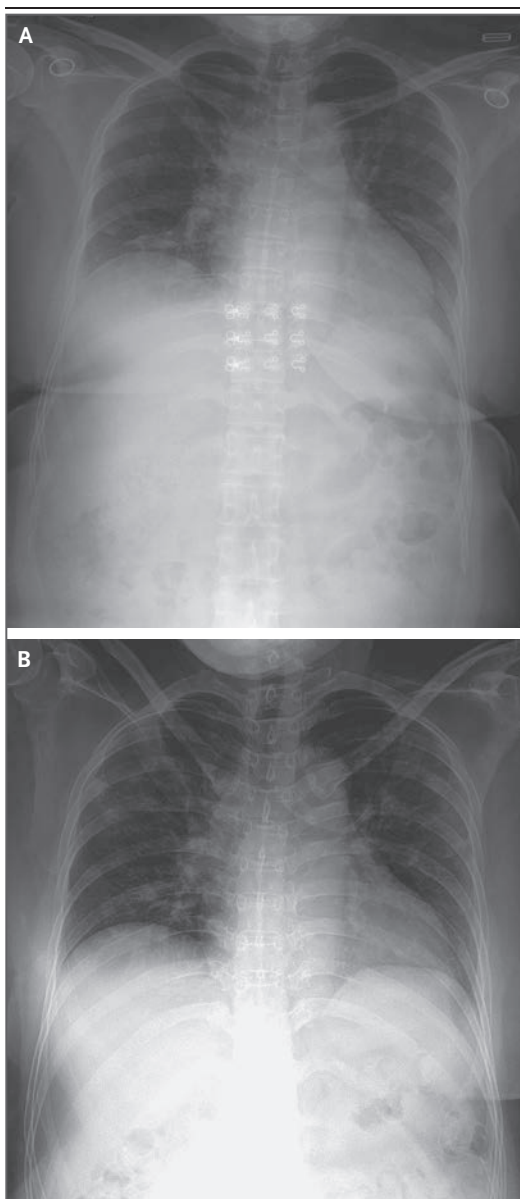
and has spread to several countries, typically by travelers returning from China.<sup>1,2</sup> Of the 3 million Taiwanese persons who work in China,

2000 work in Wuhan, so the risk of imported SARS-CoV-2 infection to Taiwan from China is high. As of January 29, there were 7 confirmed imported cases of infection with SARS-CoV-2 to Taiwan. We identified a case of locally transmitted infection in Taiwan from a wife to her husband.

On January 25, 2020, a 52-year-old woman with a history of type 2 diabetes presented with fever to an emergency department in central Taiwan. She was admitted to the hospital because of suspicion of pneumonia associated with SARS-CoV-2 infection. She had lived in Wuhan from October 21, 2019, to January 20, 2020. She returned to Taiwan from Wuhan on January 20 on an airplane. On the same day, a throat swab was obtained from another passenger on that flight; that passenger was confirmed to have the first known imported case of SARS-CoV-2 infection in Taiwan when the swab was found to be positive for the virus on January 21.

Fever and myalgia developed in the woman on January 25, a total of 5 days after she returned to Taiwan from Wuhan. She reported that she did not have cough, dyspnea, chest pain, or diarrhea. Chest radiography showed diffuse infiltrates in the bilateral lower lungs (Fig. 1A). Assays to detect influenza viruses and a respiratory panel to detect adenovirus, human rhinovirus, parainfluenza virus, respiratory syncytial virus, *Bordetella pertussis*, *Chlamydia pneumoniae*, and *Mycoplasma pneumoniae* were all negative. A throat swab was positive for SARS-CoV-2 on real-time reverse-transcription–polymerase-chain-reaction (RT-PCR) assays on January 27<sup>3,4</sup>; this was the fifth confirmed imported case of Covid-19 (the illness caused by SARS-CoV-2 infection) in Taiwan.

On day 1 of hospitalization, the patient received supportive therapies, and oseltamivir and levofloxacin were added as empirical therapy on day 3 of hospitalization after SARS-CoV-2 was detected on RT-PCR. Cough, rhinorrhea, and sore throat developed on day 5, and chest radiography revealed progressive diffuse interstitial opacities and consolidation in the bilateral parahilar areas and lower lung fields (Fig. 1B). She continued to receive supportive therapy with oseltamivir and levofloxacin, but she did not receive oxygen therapy. As of February 11, she remained hospitalized, but her vital signs were stable and she was not receiving oxygen therapy.



**Figure 1. Imaging of the Wife's Chest.**

Panel A shows diffuse infiltrates in the bilateral lower lungs on a radiograph obtained on day 1 (on admission), and Panel B shows progressive diffuse interstitial opacities and consolidation in the bilateral lower lung fields on a radiograph obtained on day 5 after admission.

The patient's 50-year-old husband is a music producer who works primarily at home in Taiwan. He reported that he had not traveled to any region where SARS-CoV-2 transmission was known to be occurring and that he had no known contacts with any person returning from such a re-

gion; this was confirmed by an investigation by the government health care unit in Taiwan. On January 21, he met his wife when she returned to Taiwan. They shared a bedroom and meals at home.

On January 25, the husband sought medical treatment at the same time as his wife. He presented only with rhinorrhea; he did not have fever, cough, dyspnea, chest pain, or diarrhea. He was admitted to the hospital because of concern regarding Covid-19, given his close contact with his wife. A complete blood count and chest radiography did not show any abnormalities. Assays for influenza viruses and a respiratory panel were negative, but SARS-CoV-2 was detected on RT-PCR on January 28.

The husband's symptoms developed on the same day as those of his wife, January 25. This suggests transmission shortly after his wife returned to Taiwan. During the hospital stay, he had rhinorrhea, and myalgia developed on January 27, but he did not have fever (see Fig. S1 in the Supplementary Appendix, available with the full text of this letter at NEJM.org). He received supportive therapy without any antiviral agents or antibiotics. As of February 11, he remained hospitalized, but his vital signs were stable and he was not receiving oxygen therapy.

Local transmission of SARS-CoV-2 infection occurred in this couple in Taiwan. So far, no secondary case from this couple has been identified.

Ying-Chu Liu, M.D.  
Ching-Hui Liao, M.D.  
Chin-Fu Chang, M.D.  
Chu-Chung Chou, M.D., Ph.D.  
Yan-Ren Lin, M.D., Ph.D.

Changhua Christian Hospital  
Changhua City, Taiwan  
h6213.lac@gmail.com

Disclosure forms provided by the authors are available with the full text of this letter at NEJM.org.

This letter was published on February 12, 2020, at NEJM.org.

1. Zhu N, Zhang D, Wang W, et al. A novel coronavirus from patients with pneumonia in China, 2019. *N Engl J Med* 2020;382:727-33.
2. Novel coronavirus (2019-nCoV): situation report-10, 30 January 2020. Geneva: World Health Organization, 2020 (<https://www.who.int/docs/default-source/coronaviruse/situation-reports/20200130-sitrep-10-ncov.pdf>).
3. Corman V, Bleicker T, Brünink S, et al. Diagnostic detection of Wuhan coronavirus 2019 by real-time RT-PCR. Geneva: World Health Organization, January 13, 2020 (<https://www.who.int/docs/default-source/coronaviruse/wuhan-virus-assay-v191527e5122341d99287a1b17c111902.pdf>).
4. Phan LT, Nguyen TV, Luong QC, et al. Importation and human-to-human transmission of a novel coronavirus in Vietnam. *N Engl J Med* 2020;382:872-4.

DOI: 10.1056/NEJMc2001573

## Total Hip Arthroplasty or Hemiarthroplasty for Hip Fracture

**TO THE EDITOR:** In a multicenter, randomized, controlled trial, the investigators who conducted the Hip Fracture Evaluation with Alternatives of Total Hip Arthroplasty versus Hemi-Arthroplasty (HEALTH) trial (Dec. 5 issue)<sup>1</sup> compared the results of total hip arthroplasty with hemiarthroplasty in elderly patients with displaced femoral neck fractures. The results should be interpreted with caution. First, patient outcomes were analyzed within 24 months after surgery. Considering that implant survivorship in hip arthroplasty generally starts to diverge 10 years after surgery, such a short-term follow-up does not allow for appreciation of the ultimate outcomes of the procedures.<sup>2</sup> It is not surprising that the authors observed such analogous postoperative outcomes in this short-term postoperative period. Second, recent studies have highlighted a similar 3-month

cost with both procedures<sup>3</sup> and have indicated an increased risk of reoperation after the conversion of hemiarthroplasty to total hip arthroplasty as compared with primary total hip arthroplasty and revision surgery.<sup>4</sup> These findings beg the question of which procedure is more clinically and economically effective. In sum, further comparisons of long-term ultimate outcomes with in-depth cost-effectiveness analyses are needed to illustrate the best treatment choice for selected patients with hip fracture.

Liang Gao, M.D.  
Saarland University Medical Center  
Homburg, Germany  
lianggao22@gmail.com

Zhijia Han, M.D.  
Shanghai General Hospital  
Shanghai, China