

## The first 2019 novel coronavirus case in Nepal

In January, 2020, the outbreak of the 2019 novel coronavirus (2019-nCoV) in China spread progressively to other countries,<sup>1,2</sup> with WHO declaring it a Public Health Emergency of International Concern.<sup>3</sup> Among the affected countries beyond China (where 12 307 cases and 259 deaths were reported as of Feb 1, 2020) are others in Asia, including Nepal.<sup>4</sup>

On Jan 13, 2020, a 32-year-old man, a Nepalese student at Wuhan University of Technology, Wuhan, China, with no history of comorbidities, returned to Nepal. He presented at the outpatient department of Sukraraj Tropical and Infectious Disease Hospital, Kathmandu, with a cough. He had become ill on Jan 3, 6 days before he flew to Nepal. He indicated no exposure to the so-called wet market in Wuhan. Throat swabs obtained from the patient tested positive for 2019-nCoV on real-time RT-PCR assays at the WHO laboratory in Hong Kong. On admission to hospital in Kathmandu, his temperature was 37.2°C (99°F), with throat congestion, but with no other relevant signs or symptoms. He was isolated and treated with broad-spectrum antibiotics and supportive therapies. After 6 h, he complained of mild breathing difficulty and had decreased oxygen saturation (SpO<sub>2</sub> 87% on room air). Chest radiographs obtained on admission showed an infiltrate in the upper lobe of the left lung (figure). On Jan 14, his temperature rose to 38.9°C (102°F) and the next day he had breathing difficulties while in the supine position, with crepitations in the right lower lung field. His fever was no longer present on Jan 16, and his clinical condition improved. He was discharged the next day and instructed to self-quarantine at home. Laboratory tests showed

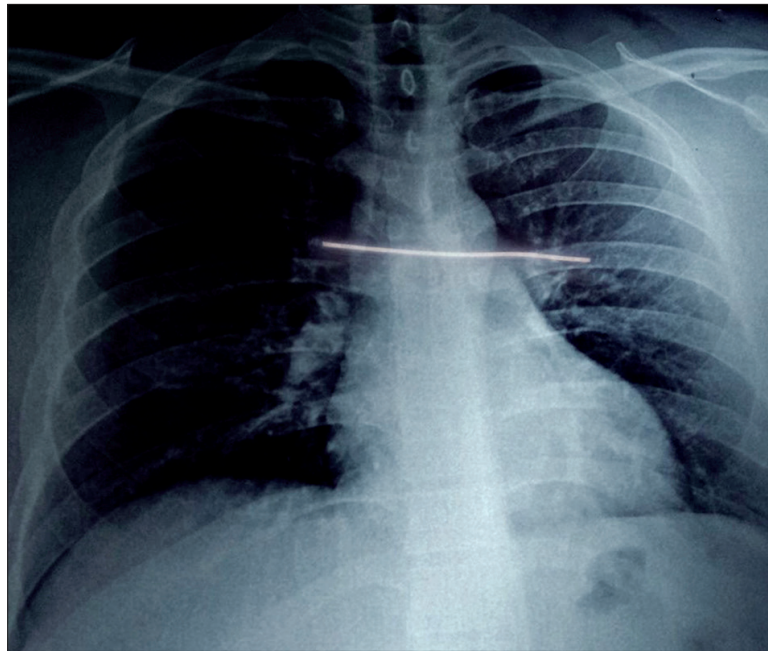


Figure: Initial radiograph of the patient

no abnormalities. Real-time RT-PCR assays for influenza A and B viruses, and NS1 antigen rapid tests for dengue viruses, scrub typhus, and *Brucella* spp were negative. Follow-up assessments on Jan 29 and Jan 31 gave an RT-PCR negative throat swab for 2019-nCoV. Informed consent was obtained from the patient to be included in this Correspondence.

Compared with other recently reported cases, which included rapid worsening and even progression to death,<sup>1,2,5,6</sup> our patient had only mild disease and survived and recovered after 13 days. A previous importation of 2019-nCoV in a family cluster in Vietnam included a father returning from Wuhan who transmitted the virus to his wife and son. They all recovered in less than 2 weeks.<sup>5</sup> In two cohorts in China (n=41, n=99), the case fatality rates were 15%<sup>1</sup> and 11%.<sup>7</sup> Some reports have indicated that few patients with 2019-nCoV infection have prominent upper respiratory tract signs and symptoms (eg, sore throat),<sup>1,7</sup> as occurred with the Nepalese student. As expected, fever and cough are the main clinical findings in patients with confirmed

2019-nCoV infection, with up to a quarter requiring admission to the intensive care unit.

Further studies in outpatient, primary care, and community settings are needed to get a full spectrum of clinical severity in imported, secondary, or autochthonous cases in all countries. These studies will be increasingly relevant as more cases of 2019-nCoV are diagnosed among people returning from Wuhan and other affected cities in China, but also among those who have acquired the infection from imported cases, even asymptomatic ones, as occurred in Germany.<sup>8</sup>

We declare no competing interests.

Anup Bastola, \*Ranjit Sah, Alfonso J Rodriguez-Morales, Bibek Kumar Lal, Runa Jha, Hemant Chanda Ojha, Bikesh Shrestha, Daniel KW Chu, Leo L M Poon, Anthony Costello, Kouichi Morita, Basu Dev Pandey ranjitsah@iom.edu.np

Sukraraj Tropical and Infectious Disease Hospital, Kathmandu, Nepal (AB, BS, BDP); National Public Health Laboratory, Kathmandu 44600, Nepal (RS, RJ); Global Health and Sustainable Development, University College London, London, UK (AC); Public Health and Infection Research Group, Faculty of



Lancet Infect Dis 2020

Published Online

February 10, 2020

[https://doi.org/10.1016/S1473-3099\(20\)30067-0](https://doi.org/10.1016/S1473-3099(20)30067-0)

S1473-3099(20)30067-0

- Health Sciences, Universidad Tecnologica de Pereira, Pereira, Risaralda, Colombia (AJR-M); Epidemiology and Disease Control Division, Government of Nepal, Kathmandu, Nepal (BKL, HCO); School of Public Health, LKS Faculty of Medicine, The University of Hong Kong, Hong Kong Special Administrative Region, China (DKWC, LLMP); and Department of Virology, Institute of Tropical Medicine, Nagasaki University, Nagasaki, Japan (KM)
- 1 Huang C, Wang Y, Li X, et al. Clinical features of patients infected with 2019 novel coronavirus in Wuhan, China. *Lancet* 2020; published online Jan 24. [http://dx.doi.org/10.1016/S0140-6736\(20\)30183-5](http://dx.doi.org/10.1016/S0140-6736(20)30183-5).
  - 2 Chan JF-W, Yuan S, Kok K-H, et al. A familial cluster of pneumonia associated with the 2019 novel coronavirus indicating person-to-person transmission: a study of a family cluster. *Lancet* 2020; published online Jan 24. [http://dx.doi.org/10.1016/S0140-6736\(20\)30154-9](http://dx.doi.org/10.1016/S0140-6736(20)30154-9)
  - 3 WHO. Statement on the second meeting of the International Health Regulations (2005) Emergency Committee regarding the outbreak of novel coronavirus (2019-nCoV). 2020. [https://www.who.int/news-room/detail/30-01-2020-statement-on-the-second-meeting-of-the-international-health-regulations-\(2005\)-emergency-committee-regarding-the-outbreak-of-novel-coronavirus-\(2019-ncov\)](https://www.who.int/news-room/detail/30-01-2020-statement-on-the-second-meeting-of-the-international-health-regulations-(2005)-emergency-committee-regarding-the-outbreak-of-novel-coronavirus-(2019-ncov)) (accessed Jan 2, 2020).
  - 4 WHO. Novel coronavirus (2019-nCoV)—Situation report—10–30 January. 2020. [https://www.who.int/docs/default-source/coronaviruse/situation-reports/20200130-sitrep-10-ncov.pdf?sfvrsn=d0b2e480\\_2\\_](https://www.who.int/docs/default-source/coronaviruse/situation-reports/20200130-sitrep-10-ncov.pdf?sfvrsn=d0b2e480_2_) (accessed Jan 2, 2020).
  - 5 Phan LT, Nguyen TV, Luong QC, et al. Importation and human-to-human transmission of a novel coronavirus in Vietnam. *N Engl J Med* 2020; published online Jan 28. DOI:10.1056/NEJMc2001272.
  - 6 Zhu N, Zhang D, Wang W, et al. A novel coronavirus from patients with pneumonia in China, 2019. *N Engl J Med* 2020; published online Jan 24. DOI:10.1056/NEJMoa2001017.
  - 7 Chen N, Zhou M, Dong X, et al. Epidemiological and clinical characteristics of 99 cases of 2019 novel coronavirus pneumonia in Wūhan, China: a descriptive study. *Lancet* 2020; published online Jan 30. [http://dx.doi.org/10.1016/S0140-6736\(20\)30211-7](http://dx.doi.org/10.1016/S0140-6736(20)30211-7).
  - 8 Rothe C, Schunk M, Sothmann P, et al. Transmission of 2019-ncov infection from an asymptomatic contact in Germany. *N Engl J Med* 2020; published Jan 30. DOI:10.1056/NEJMc2001468.